

Direct-to-Implant Breast Reconstruction with Simultaneous Nipple-Sparing Mastopexy Utilizing an Inferiorly Based Adipodermal Flap: Our Experience with Prepectoral and Subpectoral Techniques

Ali M. Mosharrafa, M.D.
 Tamir M. Mosharrafa, M.D.
 Victor J. Zannis, M.D.

Phoenix, Ariz.

Background: Direct-to-implant breast reconstruction continues to grow in popularity among reconstructive breast surgeons and patients alike. Women with large breasts and ptosis are often thought not to be candidates for nipple sparing or direct-to-implant reconstruction. The authors utilized a single-stage, nipple-sparing, direct-to-implant reconstruction with simultaneous mastopexy, while the nipple-areolar complex was kept viable on an inferiorly based adipodermal flap in a single stage. They report their experience and outcomes using this approach in women with breast ptosis and/or macromastia.

Methods: The authors reviewed all direct-to-implant reconstructions with simultaneous nipple-sparing mastopexies performed from June of 2015 to March of 2019. Sixty-five patients and 125 breast reconstructions were analyzed.

Results: Among the 65 patients (125 breast reconstructions), 15 (23 percent) had implants placed in the prepectoral space, and 50 (77 percent) had them placed subpectorally. Forty-seven patients (72 percent) had acellular dermal matrix used. Partial nipple-areolar complex necrosis occurred in six patients (9 percent). Other complications included partial mastectomy flap necrosis ($n = 8$ patients, 12 percent), implant exposure ($n = 3$, 4 percent), infection ($n = 1$, 1 percent), capsular contracture ($n = 4$, 6 percent), and reoperation ($n = 11$, 16 percent). Mean follow-up was 17 months (range, 3 to 47 months). There have been no cancer recurrences reported in any participants to date.

Conclusions: Nipple-sparing mastectomy with mastopexy and immediate direct-to-implant reconstruction dramatically improved the authors' results for implant-based breast reconstruction patients. The higher than expected explantation rate of 7 percent early in the study has since improved. This approach provides an opportunity to expand indications for nipple-sparing mastectomy and direct-to-implant reconstruction to women with breast ptosis and/or macromastia. (*Plast. Reconstr. Surg.* 145: 1125, 2020.)

CLINICAL QUESTION/LEVEL OF EVIDENCE: Therapeutic, IV.



Nipple-sparing mastectomy is both oncologically safe and effective in the prophylaxis and treatment of appropriately selected women with breast cancer.¹⁻³ It is associated with

superior aesthetic outcomes in many patients.⁴ The number of women undergoing nipple-sparing mastectomies continues to increase as a result of expanding oncologic indications,⁵ as well as the growing number of prophylactic mastectomies for genetic predisposition and symmetry. The aesthetic demands of patients and surgeons are also increasing, propelling techniques to improve to meet expectations.

From Mosharrafa Plastic Surgery and the Comprehensive Breast Care Center of Arizona.

Received for publication April 2, 2019; accepted July 30, 2019.

Presented at the 18th Annual Meeting of the American Society of Breast Surgeons, in Las Vegas, Nevada, April 26 through 30, 2017.

Copyright © 2020 by the American Society of Plastic Surgeons

DOI: 10.1097/PRS.0000000000006781

Disclosure: *The authors have no financial interest to disclose.*

In 1990, Bostwick⁶ first described a technique for the ptotic patient whereby the inferiorly based, de-epithelialized dermal flap was joined to the inferior pectoral border to provide a vascularized pocket covering the implant. Multiple authors have since described the technique as an alternative to using acellular dermal matrix for lower pole coverage in implant-based breast reconstruction.^{7–10}

For women with larger breasts and significant ptosis, however, nipple-sparing mastectomy is often considered a relative contraindication due to their higher rates of nipple necrosis. In addition, direct-to-implant reconstruction is usually not considered in situations in which a significant change in breast size is planned.

We have adopted the use of nipple-sparing mastectomy utilizing a Wise pattern incision design and preservation of the nipple-areolar complex on an inferiorly based, de-epithelialized, adipodermal pedicle with direct-to-implant reconstruction as a surgical plan for women with preoperative breast ptosis and/or macromastia. The novelty here is that the nipple-areolar complex is kept viable on an inferiorly based adipodermal flap in a single-stage procedure. A previously described buttonhole technique used two stages.¹¹ The objective for each patient is a single-stage reconstruction with a simultaneous mastopexy, as well as a preserved nipple-areolar complex. The technique allows for either prepectoral implant placement in patients with thick subcutaneous layers or subpectoral placement along with lower pole acellular dermal matrix for patients with thinner mastectomy flaps. Although reshaping and preservation of the nipple-areolar complex have been described in risk-reducing scenarios before and along with mastectomy,^{12,13} our series avoids this additional procedure and expands the indications to patients with breast cancer.

PATIENTS AND METHODS

Participants

We reviewed all patients in our practice who underwent nipple-sparing mastectomy with immediate mastopexy and direct-to-implant reconstruction between June of 2015 and March of 2019. Preoperative, intraoperative, and postoperative data, along with outcomes, were reviewed. Patients were selected for this procedure based on the following criteria. All were nipple-sparing mastectomy candidates based on their tumor oncology, as determined by the oncologic breast surgeons, and had clinical stage 0 through III breast cancer. Each patient had macromastia and/or preoperative breast ptosis of second degree or more. Forty-nine patients (75

percent) had grade II ptosis and 16 (25 percent) had grade III. No limit on pedicle length was identified (range, 7 to 16 cm). The patients' desired final reconstructed breast size approximated or was smaller than their preoperative breast volume. Written informed consent was obtained from each participant. No institutional review board approval was required, as this technique represents a simple modification to existing techniques. As determined by the MetroWest Medical Center Institutional Review Board chair, the activity was not defined as research by Department of Health and Human Services regulations, and therefore determined that no institutional review board was required. Patients who did not want nipple-sparing mastectomies, patients who smoked, and patients with a prior history of radiation were excluded.

Surgical Technique

Breast reconstructions were performed by two plastic surgeons (A.M.M. and T.M.M.). The plastic surgeon marked the patient preoperatively with a modification of the Wise pattern incision design. The planned final position of the nipple-areolar complex was marked first along the breast meridian at the horizontal level of the inframammary fold, transposed to the front of the breast. Diverging lines were then drawn from this point inferiorly a distance of 7 to 9 cm outside the border of the pigmented areola. The inframammary fold was then marked, the extent of which did not go beyond the fold medially or laterally. The ends of this line were then joined to the ends of the diverging lines to complete the pattern (Fig. 1).

The surgical procedure began with the plastic surgeon de-epithelializing the interior of the Wise pattern incision (Fig. 1), sparing the nipple-areolar complex, which was marked with a 38- to 45-mm-diameter "cookie cutter." The breast surgeon then proceeded with the mastectomy by first elevating the inferior flap off of the breast parenchyma, where the nipple-areolar complex dissection is a critical step to optimize preservation of the nipple-areolar complex.

The nipple-areolar preservation technique has been a controversial topic in nipple-sparing mastectomies. Initially, for oncological safety concerns, surgeons everted the nipple and cored out the ductal tissue within the nipple. This created a higher incidence of nipple necrosis. Anatomical studies of the nipple-areolar complex have shown that terminal ductal-lobular units within the nipple are uncommon.¹⁴ Furthermore, more recent series that do not core the nipple have shown low nipple-areolar complex recurrence rates. Thus, many oncologic breast surgeons now only remove the

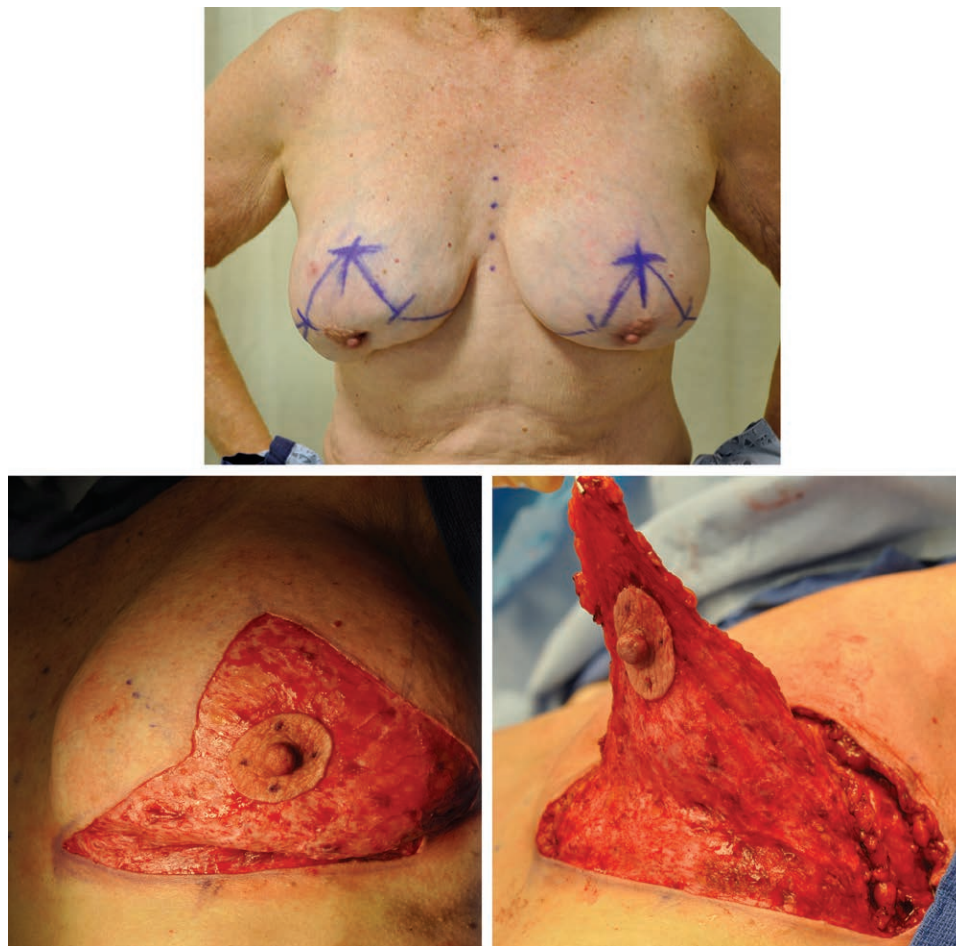

Fig. 1. (Above) Preoperative view showing incisional markings. (Below, left) Intraoperative view of de-epithelialized inferior flap. (Below, right) Intraoperative view of viable nipple-areolar complex on the elevated inferiorly based adipodermal flap.

tissue from the base of the nipple-areolar complex as a separate biopsy, leaving a thin residual layer of retroareolar tissue to preserve vascularity.^{15,16} This is, in fact, our technique. We leave several millimeters of subdermal retroareolar nipple-areolar complex tissue and routinely send a subareolar margin biopsy sample for permanent sectioning. This both minimizes nipple-areolar complex necrosis rates and confirms a negative margin.

Great care was also taken not to transect the base of the inferior flap or narrow it at the inframammary fold (Fig. 1). It should be noted that the inferior flap was similar in thickness to the superior flaps. The full thickness of the adipose layer was preserved. The flap was then wrapped gently in a warm saline lap sponge. The upper breast flaps were then dissected off the breast parenchyma, and the remainder of the mastectomy was completed. The weight of the mastectomy specimen helped guide implant size selection. Axillary surgery was performed if indicated.

The mastectomy flaps were elevated, and the decision was made regarding implant placement (subpectoral or prepectoral). The two critical factors in selecting the implant space were flap thickness and lateral mastectomy pocket dimensions. Most patients required lateral implant pocket definition with acellular dermal matrix to avoid lateral implant displacement. The implant chosen was then placed in the prepectoral or subpectoral space. If the subpectoral space was chosen, acellular dermal matrix was sewn from the inferior pectoral border to the proposed inframammary fold and lateral implant pocket boundary, avoiding injury to the adipodermal flap base. In this series, when the prepectoral space was chosen, no acellular dermal matrix was used. If the patient had a prior breast augmentation, the implant used for reconstruction was placed in the same capsule-lined pocket.

The upper breast flaps were then inset over the inferior flap and nipple-areolar complex,

burying the adipodermal flap. The viability of the nipple-areolar complex was assessed before closing the vertical limb. If it had good capillary refill, it was delivered and inset through a circular opening that had been made. If it was avascular, it was removed from the pedicle at full thickness and sewn on as a free nipple graft. A no. 15 French round drain was brought out lateral to the inframammary fold incision. A loose, nonbinding, anterior bulky bandage was applied with gauze and foam tape.

RESULTS

A total of 125 reconstructions were performed on 65 patients in this series (Table 1). Mean patient age was 50 years (range, 32 to 78 years). Routine follow-up ranged from 3 to 47 months, with an average follow-up of 17 months. All patients had grade II ptosis or worse, and 31 patients had macromastia. All patients had a preoperative diagnosis of genetic positivity or breast cancer, 23 were clinical stage 0, 21 were stage I, 16 were stage II, and five were stage III. No patients received neoadjuvant chemotherapy. One patient underwent unilateral postreconstruction external beam chest wall radiation with good soft-tissue tolerance and preservation of acceptable breast symmetry. Mastectomies were performed by one of five surgeons and reconstructions by one of two plastic surgeons. All patients underwent immediate reconstruction. In all cases, the nipple-areolar complex appeared well perfused intraoperatively and was maintained on the inferior pedicle. There were no indications for immediate free nipple grafting among the patients. Six patients developed delayed partial-thickness nipple-areolar complex necrosis and went on to heal secondarily. Eight patients had partial mastectomy flap necrosis. In six of them, necrosis was at the inverted-T closure, which was protected by the underlying adipodermal flap and healed secondarily. The other two patients had exposed underlying acellular dermal matrix and required surgical debridement and closure. There was a single peri-prosthetic infection that required explantation. Two other patients required reoperation—one prepectoral reconstruction for a dehiscence and implant exposure and the other for a hematoma. Unilateral capsular contracture occurred in four patients; one had a bilateral reconstruction with implants in the prepectoral position and three had implants in the subpectoral position. All subareolar biopsy specimens were negative for tumor and there have been no cancer recurrences

Table 1. Demographics and Intraoperative Characteristics of Direct-to-Implant Breast Reconstruction with Simultaneous Nipple-Sparing Mastopexy Utilizing an Inferiorly Based Adipodermal Flap

Characteristic	Direct-to-Implant Nipple-Sparing Mastopexy
No. (%)	65 (100)
Mean age \pm SD, yr	50 \pm 8.40
Mean body mass index \pm SD, kg/m ²	27 \pm 4.79
Mastectomy laterality, no. (%)	
Unilateral	4 (6.2)
Bilateral	61 (93.8)
Pathologic cancer stage, no. (%)	
0	23 (35.4)
I	21 (32.3)
II	16 (24.6)
III	5 (7.69)
Mean mastectomy specimen weight, g (range)	570 (150–1341)
Mean implant size inserted, cc (range)	467 (225–800)
Implant position, no. (%)	
Subpectoral	50 (76.9)
Prepectoral	15 (23.1)
Acellular dermal matrix used	47 (72.3)

reported to date (Table 2). Illustrative cases are demonstrated in Figures 2 through 4.

DISCUSSION

We have demonstrated that nipple-sparing mastectomy with direct-to-implant reconstruction in women with breast ptosis and/or macromastia is feasible with good outcomes in a single stage utilizing an immediate mastopexy and inferior dermal flap. The technique was developed by the lead author (A.M.M.) based on the simple hypothesis that this tissue would adequately perfuse the nipple-areolar complex through the subdermal plexus. The wide flap base, the entire intramammary fold, did not limit the nipple–inframammary fold distance, which ranged from 7 to 16 cm in this study. In other words, pedicle length limitations traditionally linked to breast reductions do not correlate given that the base width extends

Table 2. Complications

Complication	No. of Patients (%)
Infection	1 (1%)
Hematoma	1 (1%)
Mastectomy flap necrosis	8 (12%)
Implant exposure	3 (4%)
Capsular contracture	4 (6%)
Nipple-areolar complex necrosis	6 (9%)
Explantation required	5 (7%)
Cancer recurrence	0 (0%)

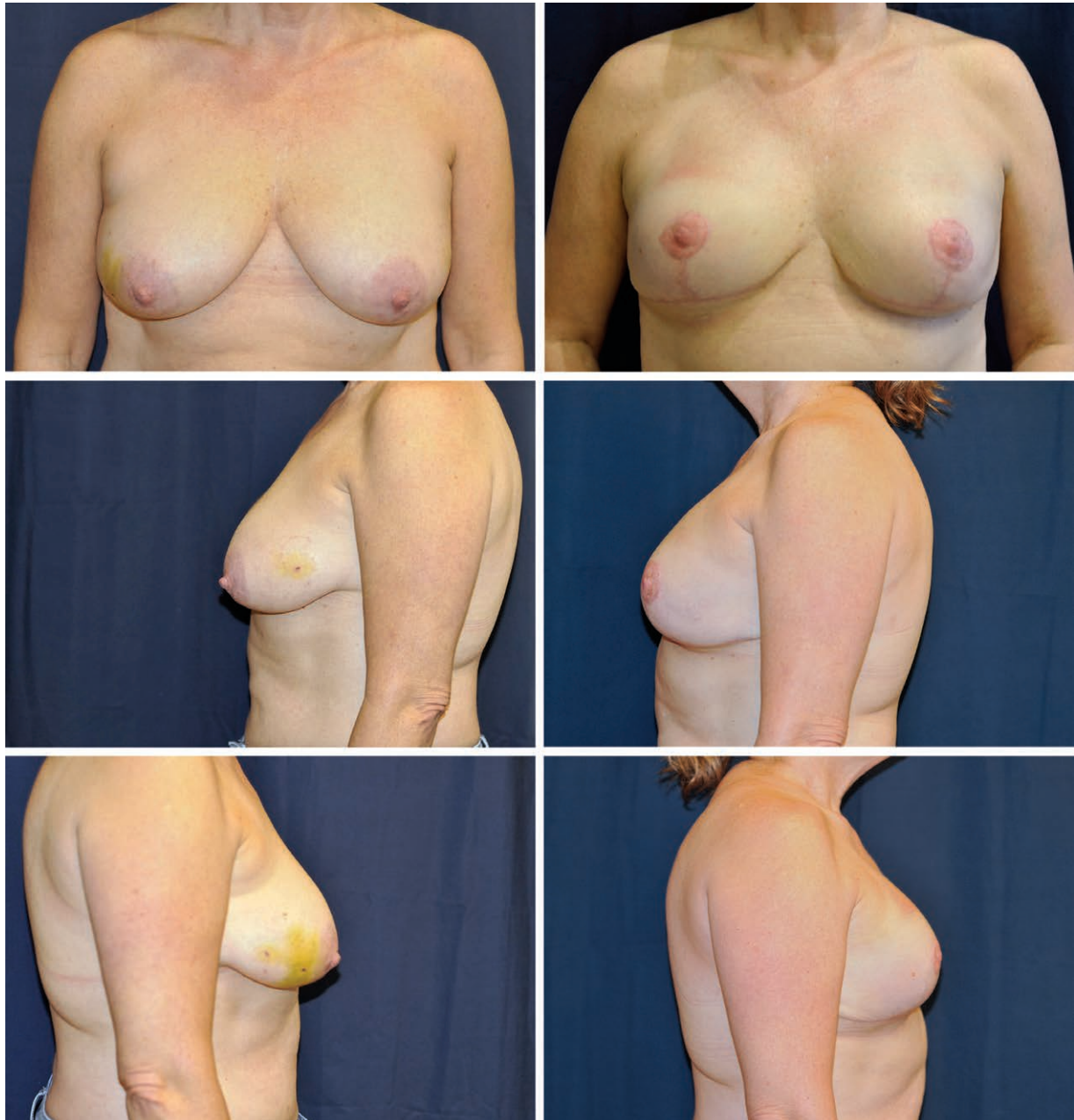

Fig. 2. A 51-year-old woman presented with right breast intraductal carcinoma and a preoperative body mass index of 33 kg/m². She underwent bilateral mastectomy with immediate direct-to-implant reconstruction with nipple-sparing mastopexy. Her mastectomy specimens weighed 821 g on the right and 736 g on the left. Anatomical 775-cc implants were used. The implants were placed in the subpectoral position with acellular dermal matrix extension. (*Left*) Preoperative views. (*Right*) Seven-month postoperative views.

along the entire inframammary fold. Patients were included regardless of age, breast size, or degree of ptosis. This now provides an option for women who otherwise may not be considered for nipple-sparing mastectomy or direct-to-implant reconstruction.

In this series, we attempted to optimize the aesthetic outcome in a single stage for women undergoing mastectomy with preoperative ptosis. Our

intention was to evaluate the reliability of the inferiorly based adipodermal flap as a vascular pedicle for the nipple-areolar complex. While there are other dermal pedicle designs for this purpose,^{11,15} the inferior design, based at the inframammary fold, allows for the greatest mobility in accurately positioning the nipple-areolar complex. Our series did represent primarily ptotic patients, with several macromastia patients included (average body

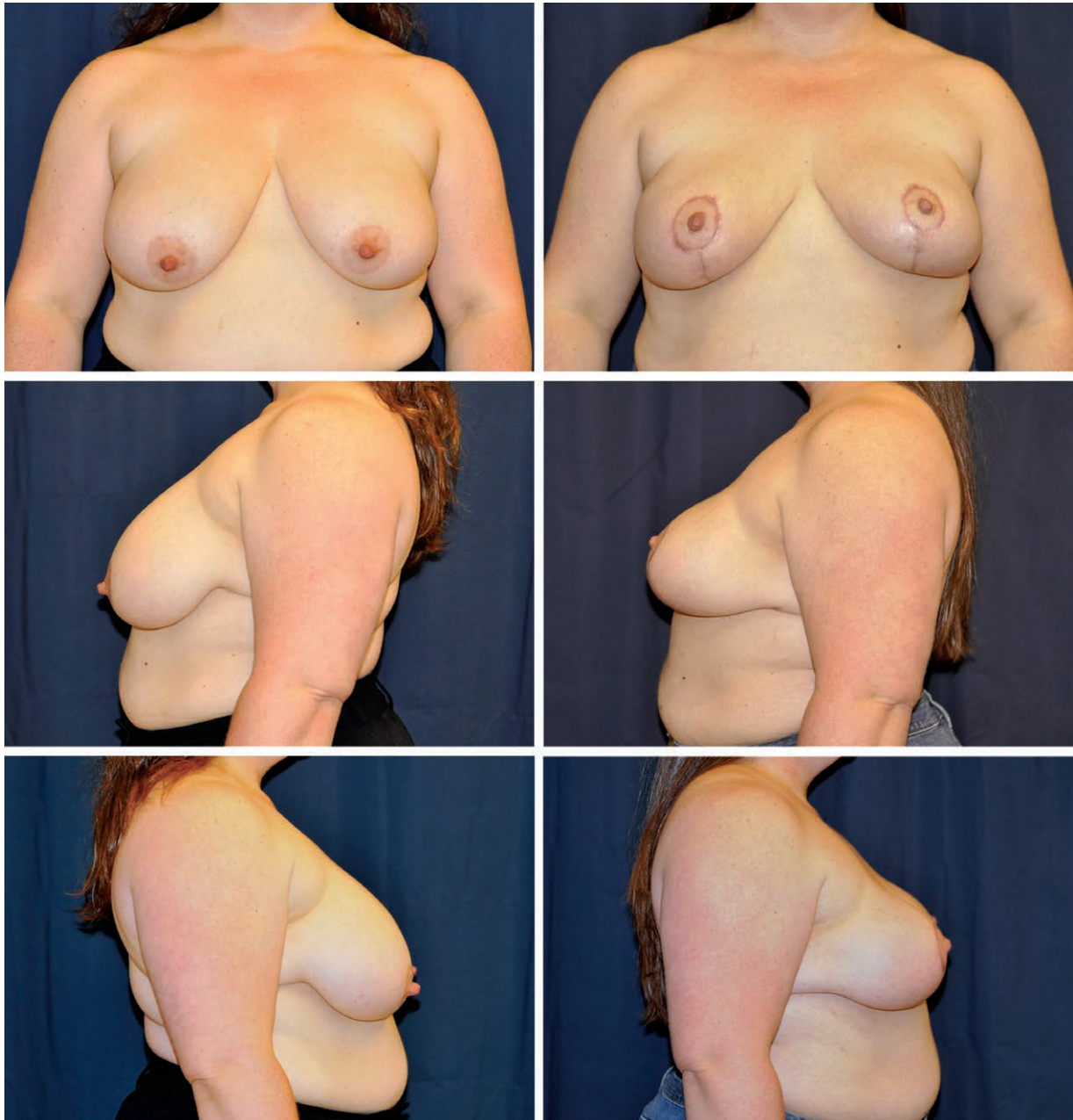


Fig. 3. A 42-year-old woman presented as *BRCA-2*-positive. Her preoperative body mass index was 39 kg/m². She underwent bilateral prophylactic mastectomy with immediate direct-to-implant reconstruction with nipple-sparing mastopexy. Her mastectomy specimens weighed 876 g on the right and 832 g on the left. Smooth round 600-cc implants were used. The implants were placed in the prepectoral position. No acellular dermal matrix was used. (*Left*) Preoperative views. (*Right*) Four-month postoperative views.

mass index was 27 kg/m²). The thickness of the flaps was similar to that of the superior flaps and varied depending on the adipose layer thickness unique to each patient. Furthermore, it provides a vascularized layer that provides nearly complete coverage of the acellular dermal matrix in the lower pole and enables healing in the event of a dehiscence or marginal necrosis at the inverted-T closure. If the skin flaps are not ideal, placement

of a tissue expander and staging the procedure is certainly an option. Access for delayed revisions was done through the lateral-most portion of the inframammary fold scar, which can be extended further laterally if necessary.

Intraoperative vascular imaging technology is certainly available and possible; however, it is not routinely utilized in our practice and thus was not used in this study. Areolar capillary perfusion

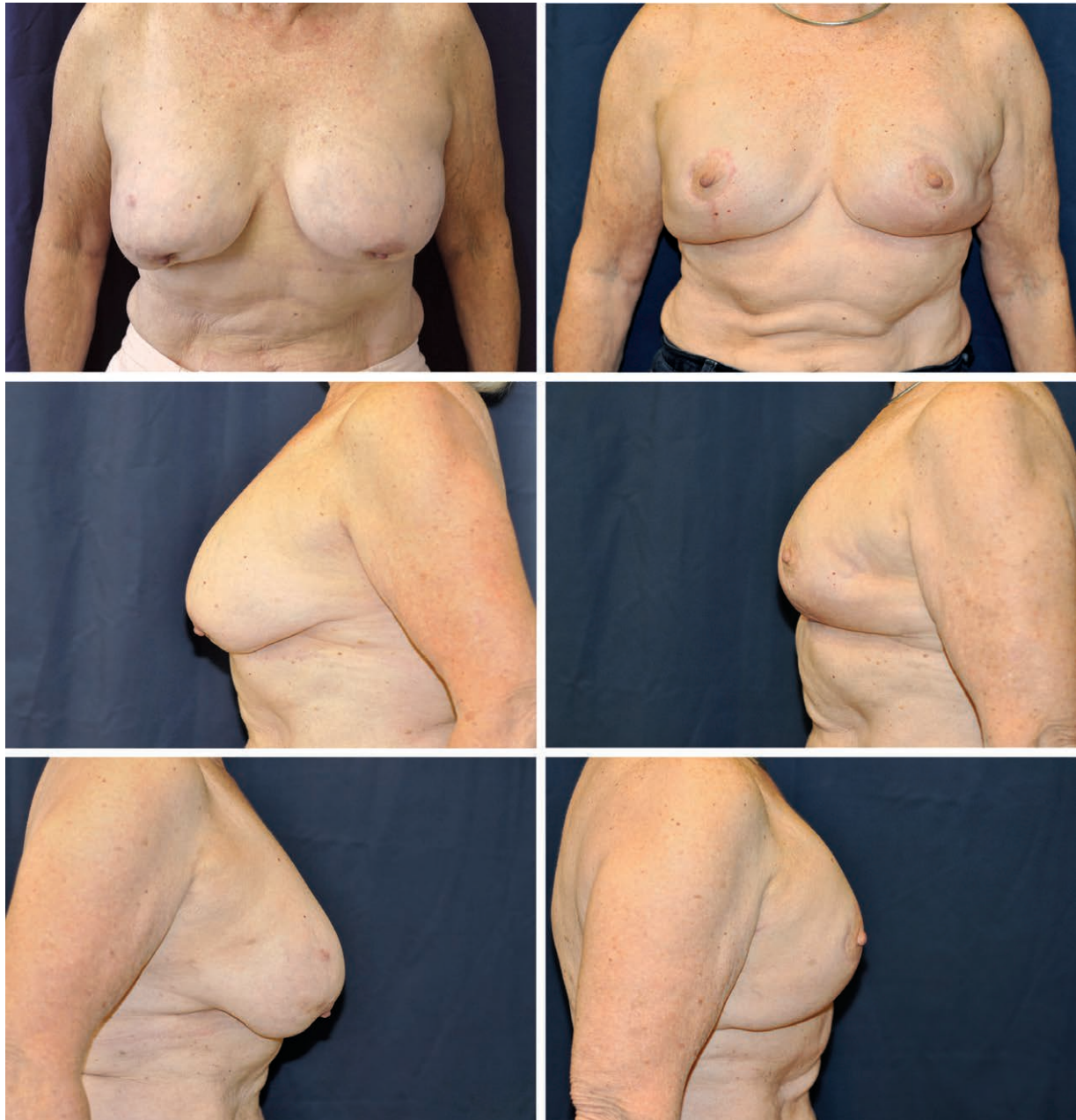

Fig. 4. A 76-year-old woman presented with left breast intraductal carcinoma. Her preoperative body mass index was 23 kg/m². She had pre-existing subpectoral silicone gel implants following breast augmentation. She underwent bilateral mastectomy, bilateral explantation, and immediate direct-to-implant reconstruction with nipple-sparing mastopexy. Her mastectomy specimens weighed 488 g on the right and 370 g on the left. Smooth round 250-cc implants were used. The implants were placed in the subpectoral position. No acellular dermal matrix was used. (Left) Preoperative views. (Right) Twenty-four-month postoperative views.

was reliable in assessing viability intraoperatively. While it was not required in the 65 women in this series, the ability to remove the nipple-areolar complex and replace it as a free nipple graft presents a viable alternative in the event its viability is compromised during flap elevation. Free nipple grafting is a possibility in all patients given the possibility of delayed vascular compromise; however,

with the 91 percent success rate in nipple-areolar complex survival demonstrated in this study, we believe an attempt at preservation is preferable.

Clearly, a critical variable in evaluating aesthetic results following nipple-sparing mastectomies is the vascularity of the mastectomy flaps.¹⁵ Though removing all of the breast tissue in a mastectomy has been a noble oncological goal, a

recent study biopsied the tissue under the skin of mastectomy flaps and demonstrated breast tissue elements within the subcutaneous layer in 51.3 percent of the specimens.¹⁷

This likely explains why there is variability in flap thickness among breast surgeons and, in turn, mastectomy flap necrosis. In our series, five mastectomy surgeons performed all nipple-sparing mastectomies in this series. The plastic surgeons' involvement was important in the gentle creation and handling of each flap. This was important in the formation of uniform flaps for this study. Importantly, the inferior adipodermal flaps were elevated in the same manner as the upper breast flaps by the general surgeon.

Patients were excluded from consideration if they refused nipple-sparing mastectomy, had a history of prior breast irradiation, or had a history of recent tobacco use. Obesity was not a contraindication, and this procedure provides a good option for these women, who often have macromastia and thicker mastectomy flaps.

The implant placement was either prepectoral or subpectoral in this series. The popularity of prepectoral placement has increased in recent years to eliminate animation deformities and accompanying patient discomfort.¹⁸ While acellular dermal matrix use can lower capsular contracture rates,¹⁹ the avoidance of acellular dermal matrix use in the prepectoral space was the result of surgeon preference. Surgeon preference was based on several factors, including mastectomy pocket dimensions, flap thickness, device availability, cost, capsular contracture risk, use of form-stable and highly cohesive implants, and experience with fat grafting at a later stage. Oncological considerations are also relevant, as imaging studies may play a role in future cancer surveillance for patients whose implants are placed in the prepectoral space.¹⁵ No local recurrences have been identified to date. The patients who experienced partial mastectomy flap necrosis (eight out of 65) were equally divided among the prepectoral and subpectoral groups. The higher-than-expected five explantations were the result of one infection, while the others occurred after partial mastectomy flap necrosis. Factors contributing to these early complications included large implant size and overly thin mastectomy flaps.

Our experience has demonstrated the critical cooperation required between breast and reconstructive surgeons. Each brings invaluable expertise to the table. Oncologically, preservation of the nipple-areolar complex is safe for patients without pathologic evidence of nipple involvement,

extensive skin involvement, or the presence of inflammatory cancer.²⁰ Our knowledge that mastectomy flap survival depends on preservation of the subdermal adipose and vascular elements is key. We now routinely work together to preserve these elements in all patients to ensure maximal removal of glandular tissue while preserving blood flow to the flaps.²¹

If we set the bar for aesthetic outcomes in alloplastic breast reconstruction following mastectomy in patients with preoperative ptosis to equal that of elective cosmetic mastopexy and breast augmentation, it follows that a viable nipple-areolar complex is a key component. In our preliminary series, the nipple-areolar complex was successfully maintained on an inferiorly based adipodermal flap in 91 percent of cases, demonstrating that this is a reliable approach. This technique has the potential to improve aesthetic outcomes for patients with ptosis and/or macromastia who are candidates for nipple-sparing mastectomy from an oncological aspect.

Ali M. Mosharrafa, M.D.

Mosharrafa Plastic Surgery
4611 East Shea Boulevard, Suite 230
Phoenix, Ariz 85028

aliplast@earthlink.net

Instagram: @mosharrafa_plastic_surgery

Facebook: MosharrafaPlasticSurgery

Twitter: @MosharrafaDocs

REFERENCES

1. Chiba A, Jakub JW, Hieken TJ. Nipple-sparing mastectomy: To spare or not to spare? *Curr Surg Rep*. 2016;4:17.
2. De La Cruz L, Moody AM, Tappy EE, et al. Overall survival, disease-free survival, local recurrence, and nipple-areolar recurrence in the setting of nipple-sparing mastectomy: A meta-analysis and systematic review. *Ann Surg Oncol*. 2015;22:3241–3249.
3. Colwell AS, Tessler O, Lin AM, et al. Breast reconstruction following nipple-sparing mastectomy: Predictors of complications, reconstruction outcomes, and 5-year trends. *Plast Reconstr Surg*. 2014;133:496–506.
4. Didier F, Radice D, Gandini S, et al. Does nipple preservation in mastectomy improve satisfaction with cosmetic results, psychological adjustment, body image and sexuality? *Breast Cancer Res Treat*. 2009;118:623–633.
5. Dent BL, Miller JA, Eden DJ, Swistel A, Talmor M. Tumor-to-nipple distance as a predictor of nipple involvement: Expanding the inclusion criteria for nipple-sparing mastectomy. *Plast Reconstr Surg*. 2017;140:1e–8e.
6. Bostwick J. Prophylactic (risk-reducing) mastectomy and reconstruction. In: *Plastic and Reconstructive Breast Surgery*. Vol II. St. Louis, Mo: Quality Medical Publishing; 1990:1369–1373.
7. Carlson GW, Bostwick J 3rd, Styblo TM, et al. Skin-sparing mastectomy: Oncologic and reconstructive considerations. *Ann Surg*. 1997;225:570–575; discussion 575.

8. Hammond DC, Capraro PA, Ozolins EB, Arnold JF. Use of a skin-sparing reduction pattern to create a combination skin-muscle flap pocket in immediate breast reconstruction. *Plast Reconstr Surg.* 2002;110:206–211.
9. Losken A, Collins BA, Carlson GW. Dual-plane prosthetic reconstruction using the modified wise pattern mastectomy and fasciocutaneous flap in women with macromastia. *Plast Reconstr Surg.* 2010;126:731–738.
10. Nava MB, Cortinovis U, Ottolenghi J, et al. Skin-reducing mastectomy. *Plast Reconstr Surg.* 2006;118:603–610; discussion 611.
11. Salibian AH, Harness JK, Mowlds DS. Primary buttonhole mastopexy and nipple-sparing mastectomy: A preliminary report. *Ann Plast Surg.* 2016;77:388–395.
12. Serrurier LC, Rayne S, Venter M, Benn CA. Direct-to-implant breast reconstruction without the use of an acellular dermal matrix is cost effective and oncologically safe. *Plast Reconstr Surg.* 2017;139:809–817.
13. Gunnarsson GL, Bille C, Reitsma LC, Wamberg P, Thomsen JB. Prophylactic nipple-sparing mastectomy and direct-to-implant reconstruction of the large and ptotic breast: Is reshaping of the challenging breast a key to success? *Plast Reconstr Surg.* 2017;140:449–454.
14. Reynolds C, Davidson JA, Lindor NM, et al. Prophylactic and therapeutic mastectomy in BRCA mutation carriers: Can the nipple be preserved? *Ann Surg Oncol.* 2011;18:3102–3109.
15. Hieken TJ, Boolbol SK, Dietz JR. Nipple-sparing mastectomy: Indications, contraindications, risks, benefits, and techniques. *Ann Surg Oncol.* 2016;23:3138–3144.
16. Ashikari AY, Kelemen PR, Tastan B, Salzberg CA, Ashikari RH. Nipple sparing mastectomy techniques: A literature review and an inframammary technique. *Gland Surg.* 2018;7:273–287.
17. Papassotiropoulos B, GÜth U, Chiesa F, et al. Prospective evaluation of residual breast tissue after skin- or nipple-sparing mastectomy: Results of the SKINI-Trial. *Ann Surg Oncol.* 2019;26:1254–1262.
18. Sigalove S, Maxwell GP, Sigalove NM, et al. Prepectoral implant-based breast reconstruction: Rationale, indications, and preliminary results. *Plast Reconstr Surg.* 2017;139:287–294.
19. Colwell AS, Damjanovic B, Zahedi B, Medford-Davis L, Hertl C, Austen WG Jr. Retrospective review of 331 consecutive immediate single-stage implant reconstructions with acellular dermal matrix: Indications, complications, trends, and costs. *Plast Reconstr Surg.* 2011;128:1170–1178.
20. Storm-Dickerson T, Sigalove NM. The breast surgeons' approach to mastectomy and prepectoral breast reconstruction. *Gland Surg.* 2019;8:27–35.
21. Storm-Dickerson T, Sigalove N. Prepectoral breast reconstruction: The breast surgeon's perspective. *Plast Reconstr Surg.* 2017;140(6S Prepectoral Breast Reconstruction):43S–48S.